

# Vented versus unvented chest seals for treatment of pneumothorax and prevention of tension pneumothorax in a swine model

**Bijan S. Kheirabadi, PhD, Irasema B. Terrazas, MS, Alexandra Koller, BS, Paul B. Allen, DSc, PA-C, Harold G. Klemcke, PhD, Victor A. Convertino, PhD, Michael A. Dubick, PhD, Robert T. Gerhardt, MD, MPH, and Lorne H. Blackbourne, MD, San Antonio, Texas**

**BACKGROUND:** Unvented chest seals (CSs) are currently recommended for the management of penetrating thoracic injuries in the battlefield. Since no supporting data exist, we compared the efficacy of a preferred unvented with that of a vented CS in a novel swine model of pneumothorax (PTx).

**METHODS:** An open chest wound was created in the left thorax of spontaneously air-breathing anesthetized pigs ( $n = 8$ ). A CS was applied over the injury, then tension PTx was induced by incremental air injections (0.2 L) into the pleural cavity via a cannula that was also used to measure intrapleural pressure (IP). Both CS were tested on each pig in series. Tidal volume ( $V_T$ ), respiratory rate, IP, heart rate, mean arterial pressure, cardiac output, central venous pressure, pulmonary arterial pressure, venous and peripheral oxygen saturations ( $SvO_2$ ,  $SpO_2$ ) were recorded. Tension PTx was defined as a mean IP equal to or greater than +1 mm Hg plus significant (20–30%) deviation in baseline levels of the previously mentioned parameters and confirmed by chest x-ray study.  $PaO_2$  and  $PaCO_2$  were also measured.

**RESULTS:** PTx produced immediate breathing difficulty and significant rises in IP and pulmonary arterial pressure and falls in  $V_T$ ,  $SpO_2$ , and  $SvO_2$ . Both CSs returned these parameters to near baseline within 5 minutes of application. After vented CS was applied, serial air injections up to 2 L resulted in no significant change in the previously mentioned parameters. After unvented CS application, progressive deterioration of all respiratory parameters and onset of tension PTx were observed in all subjects after approximately 1.4-L air injection.

**CONCLUSION:** Both vented and unvented CSs provided immediate improvements in breathing and blood oxygenation in our model of penetrating thoracic trauma. However, in the presence of ongoing intrapleural air accumulation, the unvented CS led to tension PTx, hypoxemia, and possible respiratory arrest, while the vented CS prevented these outcomes. (*J Trauma Acute Care Surg.* 2013;75: 150–156. Copyright © 2013 by Lippincott Williams & Wilkins)

**KEY WORDS:** Pneumothorax; chest seals; tension pneumothorax; combat casualty care; swine.

Penetrating chest trauma with lung perforation accounts for 5% to 6% of battlefield injuries.<sup>1</sup> In combat, hemothorax (HemoPTx) is the second leading cause of potentially preventable prehospital death and the third leading cause of mortality overall.<sup>2</sup> Unlike civilian trauma in which pneumothorax (PTx) and HemoPTx are mostly caused by blunt mechanisms (e.g., motor vehicle collisions<sup>3</sup>), in combat, these injury sequelae result primarily from gunshot wounds, explosive shrapnel, or blast overpressure injuries to the respiratory airways.<sup>2,4</sup>

The prehospital management of patients with penetrating chest wounds poses significant difficulties in the battlefield. The open, “sucking” chest wound may act as a “one-way valve,” allowing air to enter the chest with every breath but not to escape. Air accumulates in the intrapleural space and forms a pneumothorax (PTx). Another source of PTx is internal air leaks from disrupted bronchioalveolar structures if the lungs sustain

direct damage. The presence of PTx reduces physiologic negative pressure and functional residual capacity, rendering spontaneous breathing progressively difficult and inefficient. Positive-pressure ventilation may hasten development of tension PTx in an occluded chest wound with underlying lung injury and airway leak.<sup>3,5</sup>

The traditional treatment of an open chest wound (open PTx) was to place a sterile occlusive dressing on the injury and tape it to the skin on three sides, leaving one side open to allow air to escape from the chest while blocking external air from entering. While effective, no corroborating evidence existed in support of this or any other technique, and the prevailing recommendation of Committee on Tactical Combat Casualty Care was to use a completely occlusive (unvented) chest seal (CS) with close monitoring of casualties for development of tension physiology.<sup>6</sup>

Therefore, medical manufacturers responded by developing contemporary “chest seals.” As many as 15 different types of disposable adhesive CSs have been introduced into the market. Some possess a one-way venting valve that allows air to escape from the pleural cavity, but the preponderance of CS entering the current market are occlusive and have no venting valve. Most CSs meet physical requirements for military use (e.g., light weight, small size, durable, and adhesive under extreme temperature), but their functional capacities to treat PTx or HemoPTx and to prevent tension physiology are unknown. Thus, it is very difficult to identify and recommend the most clinically effective products for battlefield application.

Submitted: December 7, 2012, Revised: February 4, 2013, Accepted: March 8, 2013.  
From the US Army Institute of Surgical Research, Fort Sam Houston, San Antonio, Texas.  
This study was presented as a poster at the 26th annual meeting of the Eastern Association for the Surgery of Trauma (EAST), January 15–19, 2013, in Scottsdale, Arizona.

The opinions or assertions expressed herein are the private views of the authors and are not to be construed as official or as reflecting the views of the US Department of Defense.

Address for reprints: Bijan S. Kheirabadi, PhD, 3650 Chambers Pass, BHT2, Bldg 3610, Fort Sam Houston, TX 78234; email: Bijan.S.Kheirabadi.civ@mail.mil.

DOI: 10.1097/TA.0b013e3182988afe

The purposes of this study were to (1) develop an open PTx wound model in swine with progression to tension PTx and (2) use that model to compare the effectiveness of two popular CSs in the US military (vented Bolin vs. unvented Halo) for treatment of PTx and prevention of tension PTx,<sup>7</sup> thereby aiding with the selection of the best device.

## MATERIALS AND METHODS

This study was approved by the Animal Care and Use Committee of the US Army Institute of Surgical Research. All animals received care and were used in strict compliance with *The Guide for the Care and Use of Laboratory Animals*.<sup>8</sup>

### Animal Preparation and Instrumentation

Female Yorkshire pigs (approximately 40 kg, n = 12) were induced with an intramuscular injection of tiletamine-zolazepam (Telazol, 4–6 mg/kg), intubated, and secured on the table in a supine position. During instrumentation, animals were mechanically ventilated with positive pressure air at 8 mL/kg per breath to 10 mL/kg per breath and 8 breaths per minute to 12 breaths per minute to maintain end-tidal P<sub>CO<sub>2</sub></sub> of 40 ± 5 mm Hg. Anesthesia was provided with 1% to 3% isoflurane. Maintenance fluid (lactated Ringer's solution at 3–5 mL/kg/h) was administered through an ear vein catheter, and urine output was collected via a Foley catheter and was measured. Body temperature was monitored via a rectal probe and maintained at 37°C to 39°C. A pulse oximeter was attached to the tongue or cheek for measuring peripheral oxygen saturation levels (SpO<sub>2</sub>).

The right carotid artery was cannulated for continuous recording of blood pressure, heart rate (HR), and blood sampling. The right external jugular vein was cannulated to insert a Swan-Ganz catheter (oximetric PA catheter) into the right side of the heart for continuous measurement of central venous pressure, (CVP), pulmonary arterial pressure (PAP), mixed venous oxygen saturation (SvO<sub>2</sub>), and cardiac output (CO). A radiopaque (stainless steel) J-wire was inserted into the jugular vein and extended into the inferior vena cava as a guide for locating the mediastinum on the chest x-ray study. After instrumentation, the

animal was placed in sternal recumbent position and secured. Automatic respiration was discontinued, anesthetic gas was reduced, and the animal was allowed to breathe spontaneously (medical air) for the rest of the experiment.

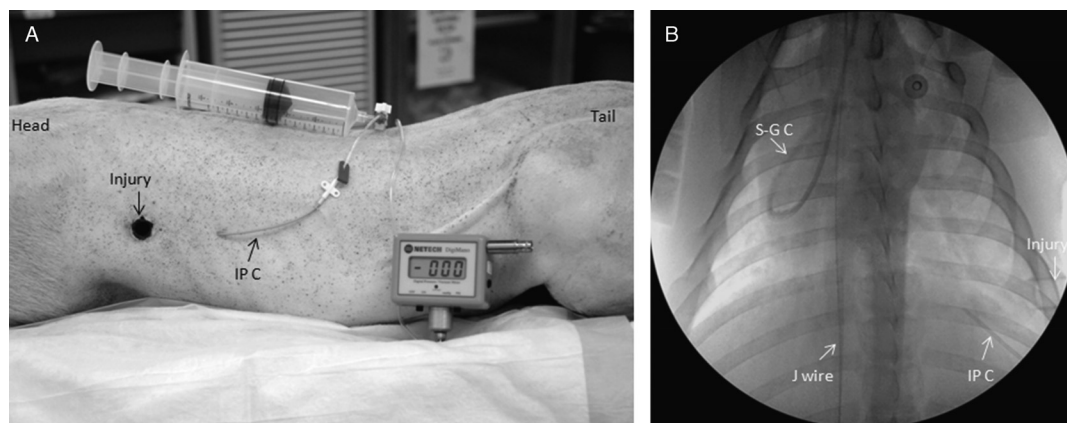
### Chest Injury and Intrapleural Pressure Measurement

Before chest injury, a 14-gauge catheter was inserted percutaneously into the left pleural space at the sixth intercostal space. This catheter was used for incremental air injection (0.2 L per injection) into the pleural cavity and intrapleural pressure (IP) measurement with a digital monometer (NETECH, DigiMano, Fig. 1A).

To produce a chest injury, an incision was made through the dermis at the left fifth intercostal space on the axillary line. A hole was then created by blunt dissection into the pleural cavity and an 11.5-mm Thoracoport with a sleeve was inserted into the chest wall without injuring the lung. The trocar was then removed, but the sleeve was left in place creating an open track between the pleural cavity and outside (Fig. 1A). Following chest injury, the hole was plugged with a rubber stopper and excess air was evacuated with a syringe reestablishing the baseline negative IPs (–1.5 mm Hg expiration and –5 mm Hg inspiration) that were measured before the chest injury. Next, a 15-minute stabilization was allowed, and then baseline values for hemodynamic and respiratory parameters (tidal volume [V<sub>T</sub>] and respiration rate [RR]) were recorded, and an arterial blood sample for blood gas analysis and a baseline chest x-ray images were obtained (Fig. 1B).

### Experimental Design

After performing four-model development experiments, eight pigs were tested according to the methods described previously. The mediastinum in pigs, unlike in humans, is variably fenestrated (incomplete), allowing air communication from one hemithorax to the other.<sup>9,10</sup> Because of this variability in mediastinum among pigs, both CSs were tested on each animal in series (paired designed test). The order of CSs was reversed after each experiment.



**Figure 1.** Experimental model of PTx and tension PTx in pigs. A, A test subject (sternal recumbency) after intrapleural cannulation and creation of an open chest wound. B, A baseline chest x-ray image after the chest wound was plugged, and excess air was withdrawn from pleural space (normal IP, IP). Note the J-wire, placed in inferior vena cava as a reference for mediastinum position. S-G C, Swan-Ganz catheter.

To induce PTx, the plug was removed from the chest hole, and free air movement into the left pleural space was allowed for 5 minutes. The resulting IP, hemodynamic, and respiratory parameters were then recorded. Next, CS 1 was placed over the hole and sealed around the chest wound. Changes in IP, hemodynamic, and respiratory parameters were recorded 5 minutes after CS application (PTx + CS). Next, increments of 200-mL air were injected into the pleural cavity every 5 minutes until either tension PTx developed or air was injected equivalent to 100% of the total lung capacity (TLC). The TLC was estimated to be approximately 55 mL per kilogram of body weight.<sup>11</sup> IP, hemodynamic, and respiratory values were recorded 5 minutes after each air injection. At the conclusion, an arterial blood sample was collected for blood gas measurement. The presence of tension PTx was defined<sup>12</sup> as a mean IP greater than +1 mm Hg and significant deviation from baseline values of at least 4 of the 5 following parameters: 30% rise of PAP, 30% fall of SvO<sub>2</sub>, 20% fall of V<sub>T</sub>, mean arterial pressure (MAP), or CO. Development of tension PTx or lack of it was confirmed with a subsequent chest x-ray study.

Once testing of the first CS was completed, it was removed, and the chest wound was plugged again. Any remaining air in the pleural cavity was evacuated with a syringe, and the baseline negative IP was restored. The animal was allowed to recover for at least 15 minutes until it regained normal and stable respiratory and hemodynamic functions. Baseline values for the next test (CS 2) were then recorded and new baseline blood sample and chest x-ray image were obtained. Next, another 5-minute open PTx was allowed and after recording the changes, the CS 2 was applied over the injury. The incremental air injections into pleural cavity were then repeated, and data were recorded as before. The animal was euthanized after final blood sample and x-ray image were obtained.

## Data Analysis

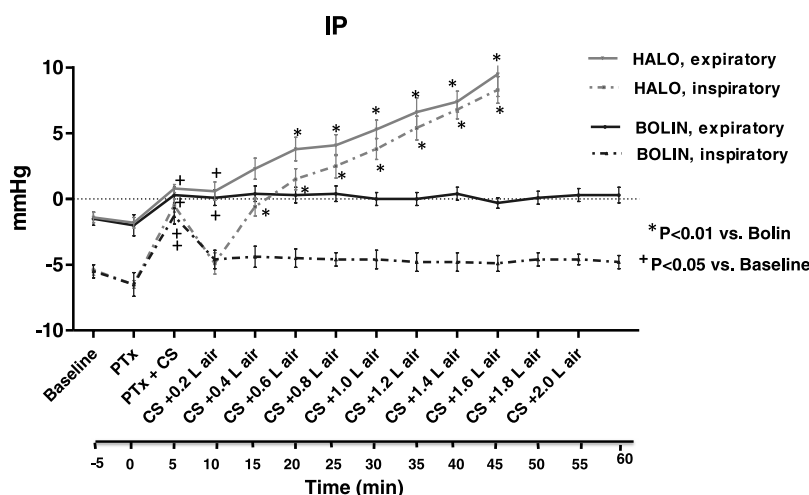
Data are expressed as mean ± SEM. Between-group analysis (Halo vs. Bolin) was performed using two-way repeated-measures analysis of variance. Bonferroni post test was used to compare replicate means at each PTx level. Within-group (treatment) analysis was performed only on the first three time points using repeated-measures analysis of variance with Dunnett's test as posttest. A  $p < 0.05$  was considered significant.

## RESULTS

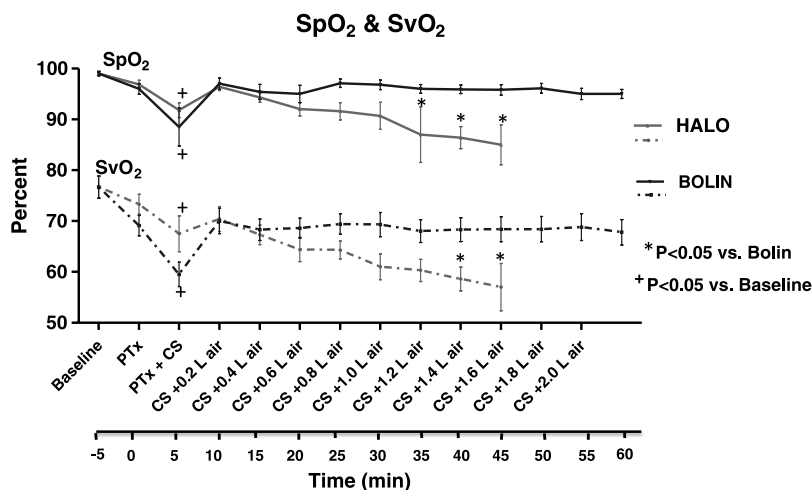
### Effects of PTx and CSs on Respiratory Function

Five minutes of open PTx in the left hemithorax produced a significant rise in IP ( $p < 0.05$ ) that approached 0 mm Hg as expected (Fig. 2) with subsequent significant reductions in percent SpO<sub>2</sub>, SvO<sub>2</sub> (Fig. 3), and PaO<sub>2</sub> levels. The V<sub>T</sub> and RR were however modestly decreased (Table 1). Covering the chest wounds with either type of CS restored most parameters (i.e., inspiratory IP, SpO<sub>2</sub>, SvO<sub>2</sub>, and V<sub>T</sub>) to near-baseline levels when measured at 5 minutes after application.

Subsequent air injection into the chest that mimicked the lung injury and gradual air accumulation in the pleural cavity produced different effects depending on which type of CS was used. With the unvented CS, the IP progressively increased to positive levels with smaller differences between inspiration and expiration IP. The V<sub>T</sub> gradually declined, but RR remained unchanged. The SpO<sub>2</sub> and SvO<sub>2</sub> gradually but significantly declined as more air was injected, and SvO<sub>2</sub> fell below hypoxic levels (<60%) after 1.2-L to 1.4-L air injection. Breathing became more strenuous, and tension PTx was eventually developed in all subjects when IP reached +10 mm Hg (average). Partial pressures of oxygen (PaO<sub>2</sub>) and carbon dioxide (PaCO<sub>2</sub>) in the final blood samples were significantly deranged at the



**Figure 2.** IP measured during inspiration and expiration cycles of pigs subjected to PTx and CS coverage and subsequent air injections. To examine the effectiveness of each CS against PTx, only the data obtained in the first three time points (i.e., baseline, PTx, and PTx + CS) were analyzed. The significant rise of IP as a result of PTx was counteracted by applying either CS. However, further intrapleural air injection could not be managed with unvented Halo CS and resulted in increased IP and the development of tension PTx. Note, the x axis notations in all the figures indicate the start of each event; the results are measured 5 minutes later and are shown in the next time point. For example, PTx was induced at 0 time, the changes in IP are seen at +5 minutes.



**Figure 3.** Peripheral oxygen saturation (SpO<sub>2</sub>, measured by pulse oximeter) and mixed venous oxygen saturation (SvO<sub>2</sub>, measured by Swan-Ganz catheter) levels of pigs during PTx, CS coverage, and subsequent air injections. The decreases in these oxygenation indicators were restored by either CSs, but further intrapleural air accumulation could not be relieved by unvented CS (Halo) and resulted in hypoxemia.

conclusion of the experiments ( $59 \pm 5$  mm Hg and  $68 \pm 3$  mm Hg, respectively). In some instances, development of tension PTx coincided with respiratory arrest, during which animals' breathing stopped suddenly and cyanosis became quite apparent. In such situations, the experiment was terminated immediately, and CS was removed, allowing PTx to be released, and spontaneous breathing was restored.

In contrast, when the vented CS was used, no significant changes in IP, V<sub>T</sub>, SpO<sub>2</sub>, SvO<sub>2</sub> (Figs. 2 and 3 and Table 1), and respiratory effort of the animals were seen even after the maximum air injection (100% of TLC). The PaO<sub>2</sub> and PaCO<sub>2</sub>

in blood samples also remained unchanged during experiments ( $86 \pm 6$  mm Hg and  $55 \pm 3$  mm Hg, respectively).

### Effects of PTx and CSs on Circulatory Function

The most prominent and immediate effect of PTx in the left pleural space was a significant increase of PAP measured at 5 minutes (Fig. 4). Little or no change was seen in other circulatory parameters such as CVP (Fig. 4), HR, CO, and MAP (Table 1) at this time. With unvented CS use, however, subsequent air injections into the pleural cavity resulted in gradual and significant increases of PAP, CVP, and HR. The CO and

**TABLE 1.** Respiratory and Circulatory Parameters Measured During PTx Induction and CS Treatment

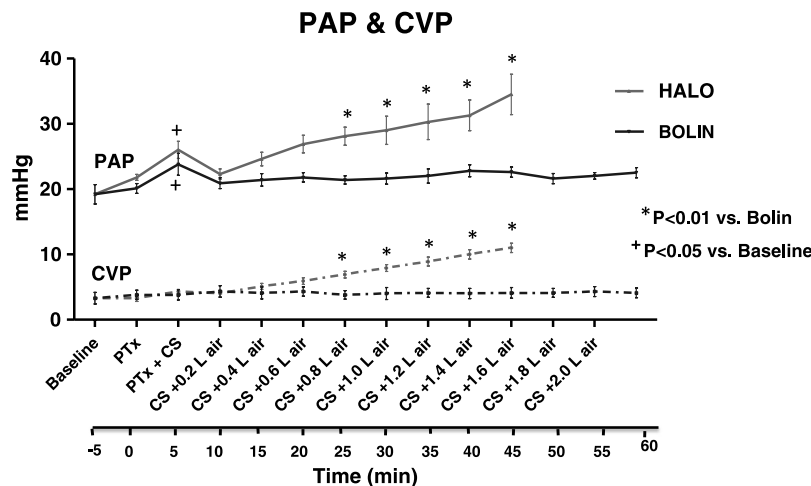
| PTx            | V <sub>T</sub> , mL |              | RR, breaths/min |         | HR, beats/min |          | MAP, mm Hg |             | CO, L/min |           |
|----------------|---------------------|--------------|-----------------|---------|---------------|----------|------------|-------------|-----------|-----------|
|                | Halo                | Bolin        | Halo            | Bolin   | Halo          | Bolin    | Halo       | Bolin       | Halo      | Bolin     |
| Baseline       | 170.5 ± 7.9         | 163.9 ± 6.6  | 34 ± 2          | 33 ± 2  | 151 ± 11      | 150 ± 11 | 94.3 ± 6.8 | 82 ± 6      | 6.2 ± 0.5 | 6.1 ± 0.4 |
| PTx            | 147 ± 13.2*         | 144.2 ± 7.2* | 29 ± 3*         | 26 ± 4* | 146 ± 10      | 147 ± 9  | 92.7 ± 2.8 | 86.8 ± 8.6  | 6.4 ± 0.5 | 6.1 ± 0.6 |
| PTx + CS       | 160 ± 7.4           | 164.5 ± 7.0  | 36 ± 3          | 35 ± 3  | 151 ± 12      | 149 ± 8  | 87.1 ± 5.7 | 80.8 ± 5.2  | 6 ± 0.4   | 5.7 ± 0.5 |
| CS + 0.2-L air | 148.8 ± 8.1         | 155.6 ± 4.9  | 34 ± 2          | 36 ± 3  | 156 ± 11      | 153 ± 9  | 89.5 ± 6.6 | 83 ± 4.8    | 5.8 ± 0.4 | 5.7 ± 0.5 |
| CS + 0.4-L air | 143 ± 7.6           | 156.9 ± 4.4  | 34 ± 2          | 36 ± 3  | 160 ± 10      | 151 ± 9  | 89.6 ± 6.4 | 81.6 ± 4.5  | 5.6 ± 0.4 | 5.7 ± 0.5 |
| CS + 0.6-L air | 135.9 ± 4.9         | 156.9 ± 4.4  | 34 ± 2          | 36 ± 3  | 168 ± 8       | 154 ± 10 | 89.4 ± 5.8 | 80.5 ± 5.0  | 5.5 ± 0.4 | 5.7 ± 0.5 |
| CS + 0.8-L air | 138.5 ± 4.9         | 149.8 ± 6.2  | 33 ± 3          | 36 ± 3  | 169 ± 8       | 154 ± 10 | 82.3 ± 6.4 | 81.5 ± 5.1  | 5.3 ± 0.4 | 5.7 ± 0.4 |
| CS + 1.0-L air | 137.7 ± 8.8         | 157.8 ± 6.1  | 36 ± 5          | 34 ± 3  | 178 ± 10      | 155 ± 10 | 80.9 ± 8.2 | 82.9 ± 4.4  | 4.9 ± 0.5 | 5.7 ± 0.5 |
| CS + 1.2-L air | 128.3 ± 6.7**       | 159.1 ± 5.0  | 35 ± 3          | 34 ± 2  | 184 ± 8       | 156 ± 9  | 79.3 ± 4.4 | 83.8 ± 4.7  | 4.9 ± 0.4 | 5.8 ± 0.4 |
| CS + 1.4-L air | 125.3 ± 7.8**       | 160 ± 3.5    | 31 ± 1          | 34 ± 2  | 187 ± 12      | 155 ± 10 | 78.8 ± 5.3 | 83.4 ± 4.8  | 4.8 ± 0.7 | 5.8 ± 0.4 |
| CS + 1.6-L air | N/A                 | 173.3 ± 7.6  | N/A             | 34 ± 3  | N/A           | 155 ± 10 | N/A        | 80.5 ± 4.39 | N/A       | 5.8 ± 0.5 |
| CS + 1.8-L air | N/A                 | 168 ± 8.5    | N/A             | 33 ± 2  | N/A           | 158 ± 8  | N/A        | 83.6 ± 5.26 | N/A       | 5.8 ± 0.5 |
| CS + 2.0-L air | N/A                 | 160.6 ± 5.5  | N/A             | 33 ± 2  | N/A           | 157 ± 9  | N/A        | 79.8 ± 3.82 | N/A       | 5.9 ± 0.5 |

\**p* < 0.01 versus baseline of corresponding CS (only the first three measurements were compared). No significant differences were found in the changes of RR, HR, MAP, and CO between Halo and Bolin CS treatment.

\*\**p* < 0.01 versus Bolin corresponding measures.

Data are expressed as mean ± SEM.

N/A, could not be measured because air infusion was discontinued.



**Figure 4.** PAP and CVP of pigs during PTx, CS coverage, and subsequent intrapleural air infusion. Note that PAP rose rapidly in the presence of PTx and returned to baseline after covering with either CS. However, the CVP, measured in the right hemithorax, did not change in response to PTx in the left hemithorax. Further intrapleural air infusion increased both PAP and CVP and led to the development of tension PTx when the chest wounds were covered with unvented CSs.

MAP minimally decreased shortly before development of tension PTx. In contrast, with vented CS coverage, air injection up to TLC produced no significant changes in the above circulatory parameters. Tension PTx developed after an average of 1.4-L air injection in all pigs when they were treated with unvented CS but did not occur with vented CS even after injection of 2 L to 2.2 L (TLC) of air.

The x-ray images at the conclusion of an unvented CS test showed nearly total collapse of the left lung and significant deviation of the mediastinum to the right side as compared with baseline images (Fig. 5A and B). The mediastinum deviation and lung collapse seen in the x-ray images were considerably less at the conclusion of a vented CS experiment (Fig. 5C and D).

## DISCUSSION

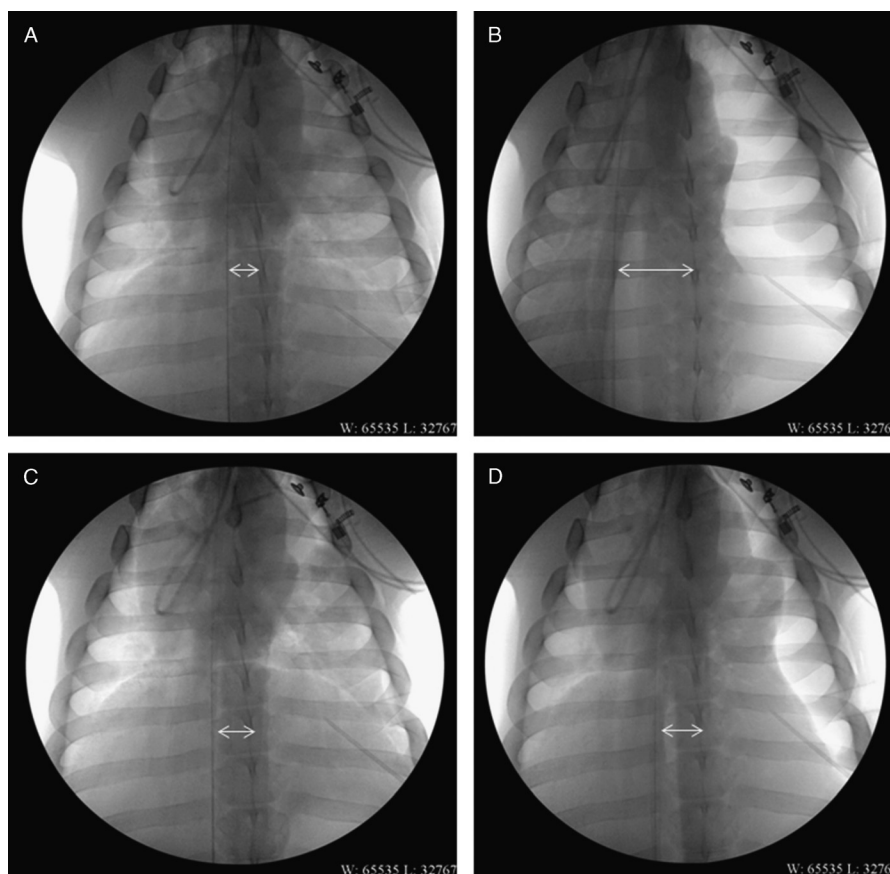
Intrathoracic tension physiology remains a significant contributor to trauma mortality, particularly in cases with penetrating or blast injury mechanisms. The current recommendation for management of penetrating thoracic injuries on the battlefield is to apply occlusive (unvented) CSs.<sup>6</sup> Since no supporting evidence existed, we investigated the effectiveness of a popular unvented CS (Halo) and compared it with a vented CS (Bolin) for treatment of PTx and prevention of tension PTx in a reproducible model of PTx in swine. Tension PTx that can develop in patients with chest/lung injury was replicated in the model by direct injection of air into the pleural cavity through a percutaneous intrapleural cannula that was also used to measure IP. This method was instrumental in determining the volume of air in the chest and the resulting IP that can lead to tension PTx in the presence of different CSs in pigs. The model also allowed easy correction of PTx by plugging the wound track and withdrawing air from the pleural cavity to reestablish physiologic IP and normalize respiratory and hemodynamic functions. Perhaps, the most valuable contribution of this model has been its focus on IP, rather than simply infusing

fixed gas volumes, both to induce and to measure the effects of tension PTx and potential mitigation strategies.

Positive-pressure ventilation increases the likelihood of development of tension PTx in patients with lung injury.<sup>1</sup> In this model, however, it was found to be protective because (a) there were no injuries to the lung and (b) positive-pressure ventilation by the automatic respirator overcame the positive IP and aerated the lungs efficiently. Therefore, experiments in this study were performed in spontaneously air breathing pigs, which also allowed observation of each animal's respiration efforts and measurement of their normal  $V_T$  and RR and subsequent changes. This was consistent with prehospital care of combat casualties who are generally not intubated by medics. The position of the anesthetized animals also affected their respiratory efficiency. The supine position generally makes breathing more difficult for four-legged animals and is known to be associated with hypoxia and an increase in pulmonary vascular shunting.<sup>13</sup> Therefore, the experiments were performed after placing the pigs in a sternal recumbent position.

Creating an open chest wound in the left thorax (free air movement in both directions) caused an immediate PTx that became evident as an increase in animal's respiration effort and partial collapse of its left lung (x-ray image). This PTx was associated with an immediate rise of IP (approaching 0 mm Hg), rapid increase in PAP, and rapid decreases in  $V_T$  and oxygen saturation measures ( $SpO_2$  and  $SvO_2$ ). Hemodynamic measures (i.e., MAP, HR, CO), however, were not significantly changed 5 minutes after PTx. In this study, the duration of open chest wounds and PTx was limited to 5 minutes to mimic the time lapse that such chest injuries may be covered with a CS in the field. Longer PTx condition without CS application could have produced more significant effects on hemodynamic function. Application of CSs (with or without venting valve) 5 minutes after PTx eased breathing efforts, reestablished negative IP, and restored most respiratory and circulatory measures.

Introduction of air into the pleural cavity, simulating airway leakage, produced widely different results. The unvented



**Figure 5.** Representative chest x-ray images of a pig subjected to PTx and treated with different CSs. The baseline (A) and final image (B) of the pig's lung when tension PTx was developed with unvented CS treatment. Note the significant deviation of the mediastinum after 1.4-L air injection. The baseline (C) and final image (D) of the same pig when treated with a vented CS and injected with maximum air volume (approximately 2.0 L).

CS application led to the development of tension PTx (confirmed by chest x-ray images) in all instances after approximately 1.4-L air injection. This was associated with a steady increase in pulmonary vascular resistance (PAP  $\uparrow$ ), decrease in lung capacity to support oxygenation (hypoxemia), and occasional respiratory arrest. In contrast, application of vented CS maintained IP near-normal levels despite repeated air injections (up to 2 L) and prevented tension PTx as defined previously. However, the chest x-ray images showed some degree of lung collapse and deviation of the mediastinum. These findings were consistent with a previous report where a one-way valve dressing was compared with occlusive gauze dressing in a canine model of open chest wound. Under spontaneously breathing condition, the one-way valve dressing was significantly more protective in preventing severe respiratory decompensation than the occlusive dressing.<sup>14</sup>

As mentioned before, tension PTx was diagnosed in this study based on positive IP and significant changes in four of the following five parameters:  $V_T$ , PAP, SvO<sub>2</sub>, CO, and MAP. The two early predictors of tension PTx often were the 20% reduction in  $V_T$  and 30% rise in PAP. The only noninvasive indicator of tension PTx was the declining SpO<sub>2</sub> as measured by pulse oximeter that paralleled with the changes in SvO<sub>2</sub>.

One parameter that frequently did not reach the critical level (20%  $\downarrow$ ) was MAP. This was consistent with the conclusion that significant hypoxemia occurs early and precedes hypotension in swine with tension PTx.<sup>15</sup> HR was elevated from the time of the injury with only small increases before tension PTx occurred. Other investigators have used a 20% decrease of MAP or a 20% increase of HR as indicators of tension PTx in a similar model of PTx in swine but in a supine position.<sup>16</sup> Given these indicators, two vented CSs (Asherman and Bolin) were tested and found to be both protective against tension PTx, with no significant difference between the two products.

This study has some limitations that need to be addressed. First, penetrating chest trauma is often associated with lung perforation and air leak into the pleural cavity. The experimental model developed here, however, did not include lung injury, and air was introduced into pleural cavity via a catheter. Although this method may create a confounding variable and does not accurately mimic the penetrating open chest injury, we think that the model is still valid for evaluating CSs and determining their effects on treating PTx and tension PTx regardless of the source of PTx. Moreover, creating a reproducible lung injury with consistent airway leak is difficult and will require invasive chest procedure that could adversely impact the animal's spontaneous

respiration. Second, the model also did not include hemothorax, another important component of penetrating chest trauma, which increases the risk of tension physiology. This was not included to simplify the model and focus this initial study on PTx and tension PTx and the impacts of CS on these injury sequelae. How the presence of blood and air in pleural cavity will be mitigated by CS—primarily vented CS since unvented CS are more likely to fail—is the subject of our next study in which increasing volumes of blood as well as air will be injected. Third, the present model represents penetrating chest trauma in spontaneously breathing subjects, which is more relevant to combat casualties in the field. In the civilian setting where most patients sustain blunt chest trauma and have no open chest wounds, CS application is unnecessary. The risk of tension PTx may be higher in these patients if they get intubated and positively ventilated before arriving at hospitals.

## SUMMARY AND CONCLUSION

We have developed a reproducible open PTx model in spontaneously air breathing pigs in the sternal recumbent position. This model was used to compare the effectiveness of an unvented CS, a more preferred and used in the US military, with a vented CS for treatment of PTx and prevention of tension PTx. We observed that both vented and unvented CSs provided immediate improvement in respiratory function and increased blood oxygenation when applied over open chest wounds. However, in the presence of additional PTx, the use of the unvented CS led to tension PTx, hypoxemia, and possible respiratory arrest. We contend that these observations are likely to translate to human patients and the application of an unvented CS without continued monitoring and the availability of a medical practitioner skilled in the identification and management of tension PTx and HemoPTx may actually increase morbidity and mortality. In contrast, the vented CS prevented increased IP and protected our subjects from tension PTx and its consequences. While further investigation into this issue is warranted, we recommend in the interim and based on these data and previous reports<sup>14,16</sup> that vented CS should be preferably used during combat casualty care, particularly in the interval before the presence of experienced emergency medical practitioners.

## AUTHORSHIP

All authors were involved in the design of the study, methodology development, and preparation and review of the manuscript. B.S.K., I.B.T. and A.K. performed the surgical procedures, treatments, data collection, and analysis. B.S.K. drafted the manuscript. R.T.G., H.G.K. and M.A.D. contributed in interpretation, discussion, commentary, and editing of

the manuscript. The study was initiated and conducted under L.H.B.'s leadership with his continued support.

## ACKNOWLEDGMENT

We sincerely thank our Veterinary Support Branch for their continued support in conducting these experiments, particularly Mrs. Shawn Chamrad for her excellent assistance in providing anesthesia. We also greatly appreciate the technical assistance by Dr. Adekoye Sanni.

## DISCLOSURE

The funding for this work was provided solely by the US Army Medical Research and Materiel Command.

## REFERENCES

1. Peoples GE, Gerlinger T, Craig R, Burlingame B. Combat casualties in Afghanistan cared for by a single team during the initial phase of operation enduring freedom. *Mil Med.* 2005;170:462–468.
2. McPherson JJ, Feigin DS, Bellamy RF. Prevalence of tension pneumothorax in fatally wounded combat casualties. *J Trauma.* 2006;60:573–578.
3. Barton ED, Epperson M, Hoyt DB, et al. Prehospital needle aspiration and tube thoracostomy in trauma victims: a six-year experience with aeromedical crews. *J Emerg Med.* 1995;13:155–163.
4. Di Bartolomeo S, Sanson G, Nardi G, et al. A population-based study on pneumothorax in severely traumatized patients. *J Trauma.* 2001;51:677–682.
5. Leigh-Smith S, Harris T. Tension pneumothorax—time for a rethink? *Emerg Med J.* 2005;22:8–16.
6. Available at: [http://www.health.mil/Libraries/110808\\_TCCC\\_Course\\_Materials/TCCC-Guidelines-110808.pdf](http://www.health.mil/Libraries/110808_TCCC_Course_Materials/TCCC-Guidelines-110808.pdf). Accessed November 30, 2012.
7. Available at: [http://www.health.mil/Libraries/110808\\_TCCC\\_Course\\_Materials/NOMLLC-TCCC-Equipment-Evaluation-Summary-120329.pdf](http://www.health.mil/Libraries/110808_TCCC_Course_Materials/NOMLLC-TCCC-Equipment-Evaluation-Summary-120329.pdf). Accessed November 30, 2012.
8. Institute of Laboratory Animal Resources, National Research Council. *Guide for the Care and Use of Laboratory Animals*. Washington, DC: National Academy Press; 1996.
9. Maloney JV Jr, Schmutzter KJ, Raschke E. Paradoxical respiration and “pendelluft”. *J Thorac Cardiovasc Surg.* 1961;41:291–298.
10. Kilburn KH. Cardiorespiratory effects of large pneumothorax in conscious and anesthetized dogs. *J Appl Physiol.* 1963;8:279–283.
11. Gustman P, Yerger L, Wanner A. Immediate cardiovascular effects of tension pneumothorax. *Am Rev Respir Dis.* 1983;127:171–174.
12. Holcomb JB, McManus JG, Kerr ST, Pusateri AE. Needle versus tube thoracostomy in a swine model of traumatic tension hemopneumothorax. *Prehosp Emerg Care.* 2009;13:18–27.
13. Rutherford RB, Hurt HH, Brickman RD, Tubb JM. The pathophysiology of progressive tension pneumothorax. *J Trauma.* 1968;8:212–227.
14. Ruiz E, Lueders J, Peresen C. A one-way valve chest wound dressing: evaluation in a canine model of open chest wounds. *Ann Emerg Med.* 1993; 22:922, abstract.
15. Barton ED, Rhee P, Hutton KC, et al. The pathophysiology of tension pneumothorax in ventilated swine. *J Emerg Med.* 1997;15:147–153.
16. Arnaud F, Tomori T, Teranishi K, et al. Evaluation of chest seal performance in a swine model: comparison of Asherman vs. Bolin seal. *Injury.* 2008; 39:1082–1088.